



DETECTION OF SKIN CANCER BY USING AN CAD BASED REAL TIME SEGMENTATION AND CLASSIFICATION

M.Malathi & P.Mohana lakshmi Department of Computer Science and Applications, D.K.M. College for women, Vellore, India. malathi3193@gmail.com & mohanalakshmi159@gmail.com

ABSTRACT:

Incidence of skin cancer has been increasing over the decades and early treatment is becoming more and more important. Detection of skin cancers is difficult due to the confusing appearance of wide variety of skin lesions. Melanomas and nevi are especially difficult to differentiate. Even with dermoscopy, which uses a magnifying glass with polarization filter and a uniform light source, the accuracy of melanoma diagnosis by expert dermatologist's remains at 75-84%. Biopsy provides a definitive diagnosis, however it can cause metastasis and therefore is only allowed based on the premise of following surgical operation within a month. In addition, these are invasive operations and make unpleasant experiences to the patient.

Keywords: Segmentation, ABCD, Melanoma, Features, Image Processing, Dermatoscopy.- Skin Cancer, Melanoma, CAD.

I INTRODUCTION

MELANOMAS

The Four Basic Types Melanomas fall into four basic categories. Three of them begin meaning they occupy only the top layers of the skin and sometimes become invasive; the fourth is invasive from the start. Invasive melanomas are more serious, as they have penetrated deeper into the skin and may have spread to other areas of the body.

Superficial spreading melanoma is by far the most common type, accounting for about 70 percent of all cases. This is the one most often seen in young people. As the name suggests, this melanoma grows along the top layer of the skin for a fairly long time before penetrating more deeply.

Lentigomaligna is similar to the superficial spreading type, as it also remains close to the skin surface for quite a while, and usually appears as a flat or mildly elevated mottled tan, brown or dark brown discoloration. This type of *in situ* melanoma is found most often in the elderly, arising on chronically sun-

exposed, damaged skin on the face, ears, arms and upper trunk. Lentigomaligna is the most common form of melanoma in Hawaii. When this cancer becomes invasive, it is referred to as lentigomaligna melanoma.

Acrallentiginous melanoma also spreads superficially before penetrating more deeply. It appears as a black or brown discoloration under the nails or on the soles of the feet or palms of the hands. This type of melanoma is sometimes found on dark-skinned people. It is the most common melanoma in African-Americans and Asians, and the least common among Caucasians.

Nodular melanoma is usually invasive at the time it is first diagnosed. The malignancy is recognized when it becomes a bump. It is usually black, but occasionally is blue, gray, white, brown, tan, red or skin tone. The most frequent locations are the trunk, legs, and arms, mainly of elderly people, as well as the scalp in men. This is the most aggressive of the melanomas, and is found in 10 to 15 percent of cases.

BASAL CELL CARCINOMA

BCCs are abnormal, uncontrolled growths or lesions that arise in the skin's basal cells, which line the deepest layer of the epidermis (the outermost layer of the skin). BCCs often look like open sores, red patches, pink growths, shiny bumps, or scars and are usually caused by a combination of cumulative and intense, occasional sun exposure.

BCC almost never spreads (metastasizes) beyond the original tumor site. Only in exceedingly rare cases can it spread to other parts of the body and become life-threatening. It is the most frequently occurring form of all cancers. More than one out of every three new cancers is a skin cancer, and the vast majority are BCCs.

NEVI

Nevi are unusual benign moles that may resemble melanoma. People who have them are at increased



risk of developing single or multiple melanomas. The higher the number of these moles someone has, the higher the risk; those who have 10 or more have 12 times the risk of developing melanoma compared to the general population. Dysplastic nevi are found significantly more often in melanoma patients than in the general population.

Those who have dysplastic nevi plus a family history of melanoma (two or more close blood relatives with the disease) have an extremely high risk of developing melanoma.

SEBORRHEIC KERATOSES (SKS)

Seborrheic keratoses (SKs) are common, non-cancerous lesions that grow on the epidermis (outer layer of the skin) and can develop on any part of the body. SKs usually begin as rough, itchy bumps and can thicken and darken to a brown or black color over time. They are usually round- or oval-shaped growths with an elevated, rough surface and sometimes seem to be glued to the skin or dropped on like candle wax. SKs are not a sign of serious health issues except in very rare instances, when they can develop suddenly in very large numbers and can be associated with internal malignancies. Although harmless, SKs should be observed regularly, like the rest of your skin, for any changes in size, shape or color. Any growth that bleeds, itches or becomes irritated should be checked by a dermatologist.

II RELATED WORKS

The skin pattern was extracted from WLC skin images by high-pass filtering. [1] A local tensor matrix was computed. The local isotropy was measured by the condition number of the local tensor matrix. The difference of this measure over the lesion and normal skin areas, combined with the local line direction and the ABCD features, was used as a lesion classifier.[2] A novel automatic border detection method based on color space analysis and clustering-based histogram thresholding. The method determines the optimal color channel and applies hybrid thresholding followed by morphological operations to detect the lesion borders. The color optimization process is tested on a set of 30 dermoscopy images, with four sets of dermatologist-drawn borders taken as the ground truth.

[3] Computer-aided diagnosis system for melanoma. The system covers the main diagnosis components of

segmentation, feature extraction, feature selection, and classification. We have elected to use both manual (under dermatologists' guidance) and automated (by applying the hybrid border-detection method) borders in the segmentation step. This we believe is essential in accurately assessing the ability of diagnostic system in both semi and fully automated manners.

[4] An automatic segmentation program for detecting borders of skin lesions in dermoscopy images. The method consists of a pre-processing phase, general lesion segmentation phase, including illumination correction, and bright region segmentation phase. [5] An automated method for detecting lesion borders in dermoscopy images using ensembles of thresholding methods. [6]Enhanced lesion discrimination capability over either information source separately. This research highlights the potential of data fusion as a model for the diagnostic process.

III SEGMENTATION

In melanoma, the pigment network usually ends abruptly at the periphery and has irregular holes, thickened and darkened network lines, and treelike branching at the periphery where pigment network features change between bordering regions. Some areas of malignant lesions manifest as a broad and prominent pigment network, while others have a discrete irregular pigment network. The pigment network also may be absent in some areas or the entire lesion.

A. Border Detection

From each skin lesion image, we extracted the border between the tumor and the surrounding normal skin area. Accurate border detection usually results in better classification performance. Conventional automated methods of border detection mostly focused on only melanocytic skin lesions (MSLs). In our previous study, we developed a general border detection algorithm for both MSLs and NoMSLs. The core of the algorithm is color thresholding, removal of artifacts such as microscope border and hair, and inclusion of bright area seen specifically in NoMSLs.



B. Feature Extraction

After determining the border of the tumor, we segmented the skin lesion image into four regions as illustrated normal skin, peripheral, central tumor and whole tumor. The whole tumor consists of all pixels within the extracted border. In contrast, the normal skin is all pixels on the outside of the border. The peripheral is the first 30% of the whole tumor area, obtained by going inward from the border as in our previous studies. Finally, the central tumor is obtained by removing the peripheral from the whole tumor

C. Classification

In this section, we introduce the proposed layered model as the primary classification model. The letters M, N, B, and S is used to denote melanoma, nevus, BCC, and SK, respectively. We used linear classifiers over non-linear ones in order to gain a clear understanding of the relationship between the inputs and the outputs of the models and to facilitate a comparison of classification performance. 1) Layered model (proposed): The first-step classifier “MN-BS” identifies the input skin lesion as MSL if the output value is greater than the classifier’s threshold value or as NoMSL otherwise. These are shown by (+) and (–) in . 3. If the result is an MSL, the second-step classifier “M-N” distinguishes melanoma from nevus in the same manner by comparing its output value with the threshold value. If the result from the first-step classifier is a NoMSL, the second step classifier “B-S” distinguishes BCC from SK. The idea of the layered model is to decompose the whole classification task to

- 1) the broad classification of MSL and NoMSL by the “MN-BS” and
- 2) the detailed classification of “melanoma and nevus” and that of “BCC and SK” by the “M-N” and “B-S”, respectively.

It may be inferred that the first-step classifier “MN-BS” must have high accuracy because misclassifications at this phase are fatal. We designed this model based on the results of our past studies that distinguishing MSLs from NoMSLs is relatively easy [30]. One of the most important steps for classifier development is feature selection. It is well-known that too many features or irrelevant features lead to poor performance and the over-fitting problem. Therefore, it is necessary to select an

appropriate subset of features for each of the classifiers “MN-BS”, “M-N”, and “B-S”. We adopted Wilks’ Lambda stepwise feature selection method [35] as in our previous studies. This algorithm begins with no selected features and repeats the step of adding or removing a feature one by one iteratively. The feature added is the one which gives the highest increase in linear regression fitness under the F-test ($p < 0.05$).

A feature is removed when it no longer contributes to the linear regression fitness ($p > 0.10$). This iterative process of adding and removing features continues until no features pass the test for addition or removal. After selecting the input features, we trained the linear classifiers. The assigned supervisory outputs were either +1 or –1 as specified by (+) and (–). After the training step, we adjusted the threshold values of the three linear classifiers by full search to optimize classification performance, e.g. detection rate of melanoma.

In our preliminary experiment, we also tested a different layered model which distinguishes cancer (melanoma and BCC) from no-cancer (nevus and SK) at the top level. However, the performance was not satisfactory mainly because of the difficulty in the classification between cancer and no-cancer. 2) Flat models (performance baseline): We introduce two types of flat models, namely the “Flat model I” and the “Flat model II” as the performance baseline. Each of the flat models has four linear classifiers: “M”, “N”, “B”, and “S” whose output values estimate the presence/absence of the corresponding classes: melanoma, nevus, BCC, and SK, respectively. This kind of classification model is typically used for multiclass classification

To the best of our knowledge, none of the available commercial programs and systems can extract and analyze the dermoscopy structures comprehensively. In these systems, the vast majority of features which are used are based on general image processing methods of color or common texture analysis. Where texture features are employed, they are often used blindly, and an image processing method is applied directly without consideration for what exactly is being quantified or how it relates to clinical concepts. At very most, texture features use some aspects of the much simpler and less accurate ABCD rule that only considers general lesion characteristics instead of shape, color



and geometric features of dermoscopy structures. Asking a computer to make a diagnosis without finding any dermoscopy structure is similar to asking a general physician without dermoscopy knowledge to make a diagnosis.

Therefore, to have a comprehensive computer-aided diagnostic system, extraction and analysis of dermoscopy structures is an essential step. We believe that with new advances in dermoscopy, the texture analysis problem should be changed to an object recognition problem that involves identification, segmentation and recognition of individual shapes and structures in skin lesions and this will be employed to identify and classify specific dermoscopic structures. It is hoped that this will lead to the development of many new approaches that can be included to increase the diagnostic accuracy of automated systems.

IV PROPOSED SYSTEM

Image Pre-processing Techniques

The acquisition of the digital image of affected skin is the first and primary step in image processing. We are using images taken from commercially available digital camera or from Epiluminescence microscopy (ELM or Dermoscopy). Once image is acquired, then it goes for preprocessing. In first part of preprocessing digital images of skin cancer, collected in Bitmap or JPEG format from different sources are converted to indexed images. It converts the ordinary image to first RGB then gray scale and at the end binary. It makes an image suitable for a particular application. The second part of pre-processing involves enhancement of image (edge highlighting, sharpening, deblurring, brightening, change in contrast, masking, hair removal, cropping or resizing and/or noise removal). For border detection of skin lesion we are using Canny Edge Detection technique.

Segmentation Techniques

Image segmentation involves image partitioning into multiple segments or regions of interest. It helps in to grouping similar characteristics regions. It is a process of extracting and representing information from the image to group pixels together with region

of similarity. In this process a label is assigned to each pixel, such that pixels with same labels share common visual characteristics. Image segmentation is used to locate skin lesions and their boundaries. We are using Watershed segmentation, because of its popularity due to generation of less complex computational results.

Feature Extraction

It applies binary mask over the entire image. It makes the dark pixel become darker and white become brighter. In threshold coding, each transform coefficient is compared with a threshold. If it is less than the threshold value then it is considered as zero. If it is larger than the threshold, it will be considered as one. The thresholding method is an adaptive method where only those coefficients whose magnitudes are above a threshold are retained within each block.

ABCD Rule of skin Cancer detection

The ABCD acronym (Asymmetry, Border irregularity, Color variegation, Diameter > 6mm). It is one of the easiest guides to the most common signs of melanoma. The characteristics needed to diagnose a melanoma as malignant are

(A) Asymmetry - Cancerous lesions are checked for symmetry. If the lesion is Symmetric (0 value) then it is benign (non-cancerous). For Cancerous cases asymmetry in zero, one (value 1), or two orthogonal axes (value 2) are considered.

(B) Border irregularity - Most of the cancerous lesions edges are ragged, notched or blurred. Its value ranges 0 to 8.

(C) Color - Cancerous skin lesion's pigmentation is not uniform. The presence of up to six known colors must be detected - white, red, light brown, dark brown, slate blue, and black. Its value ranges 0 to 6.

(D) Diameter - Cancerous lesions are greater than 6mm wide. Differential structures with at least five patterns are relevant for specific types of lesions. Any growth of a mole should be of concern. Its value ranges 0 to 5. Some melanomas do not fit the ABCD rule described above, so it is important for us to notice changes in skin markings or new spots on our skin.

Methodology

The aim of automatic computer-aided skin cancer detection/diagnosis system is to detect potentially



malignant lesions in the given/acquired images of affected skin. The processing consists of extracting the useful and desired information of the skin lesion. The main objectives of this proposed skin cancer diagnosis system are

1. To get proper information about cancer (such as Boundary, Size and distinct frequency based features) for different types of skin cancer detection.

We use following techniques:

- Edge Detection
- Segmentation and
- Classification

2. To get skin color and to decide about the nature of skin based on color pigmentation severity.

- We use fuzzy logic for quantification of cancer severity.

V RESULTS AND DISCUSSIONS

The Implementation can be done with the help of MATLAB with Image Processing Tool Box.

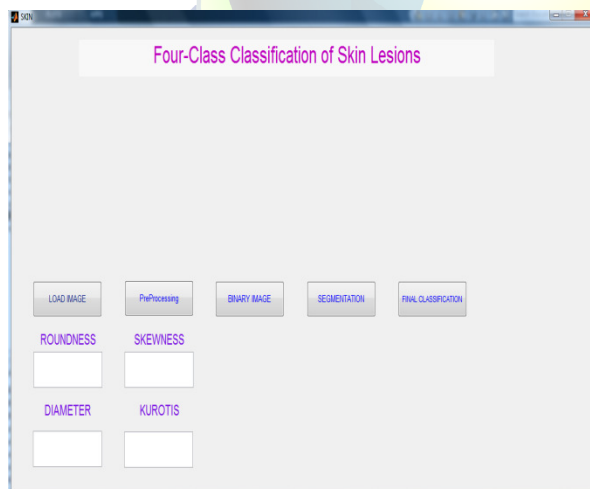


Figure 5.1 Initial Graphical User interfaces of Four Skin Classifications

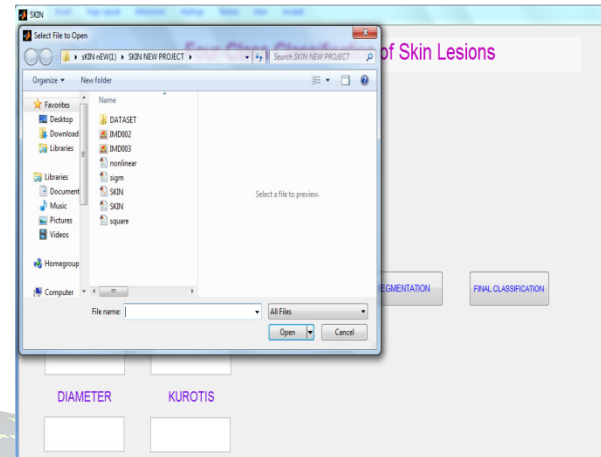


Figure 5.2 Load the Input Image

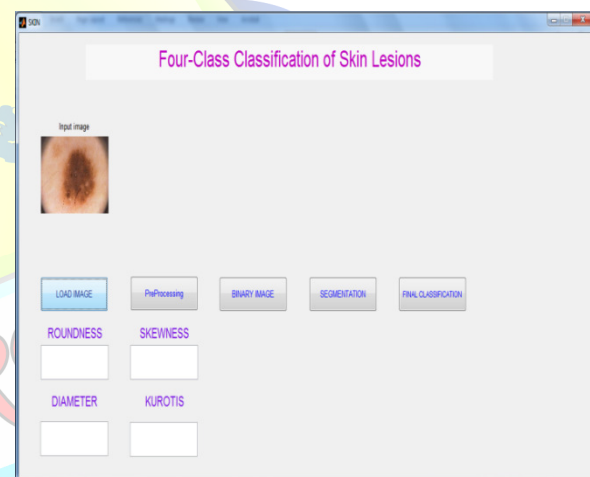


Figure 5.3 Input Image

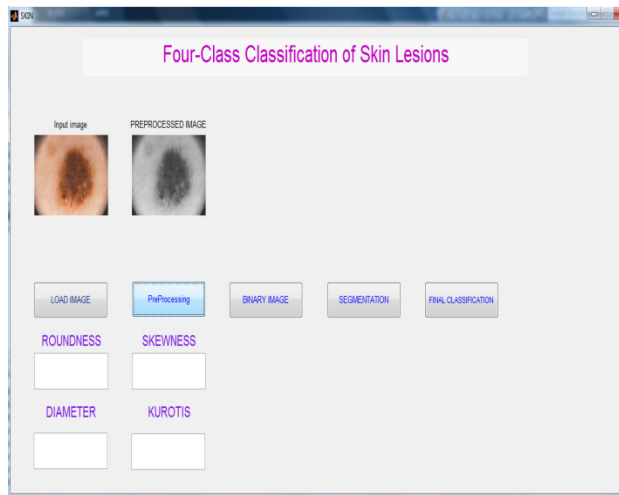


Figure 5.4 Preprocessed Image

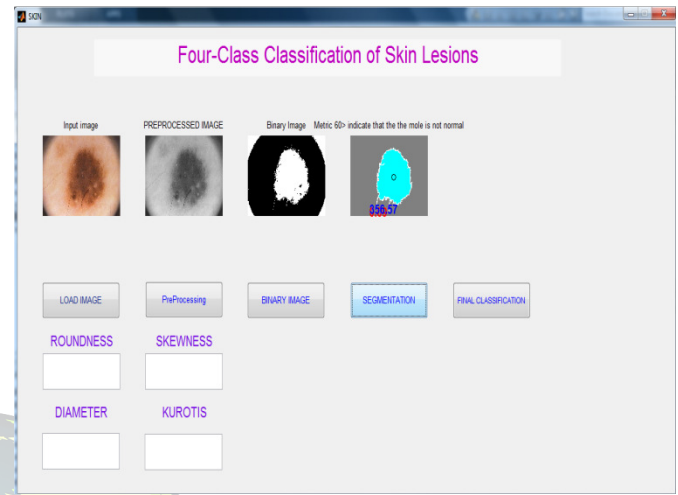


Figure 5.6 Segmented Images

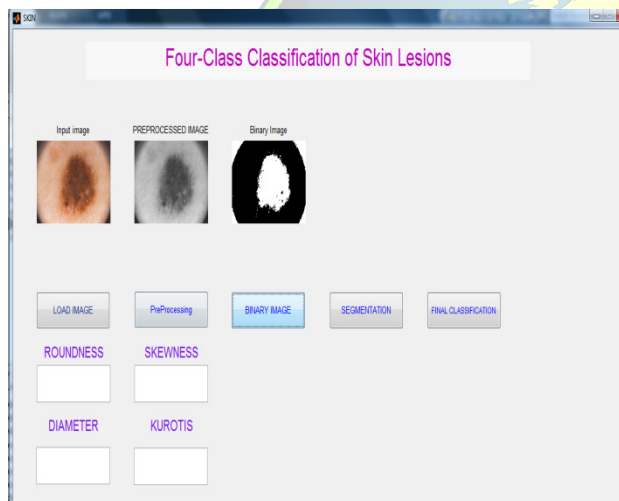


Figure 5.5 Binarised Image

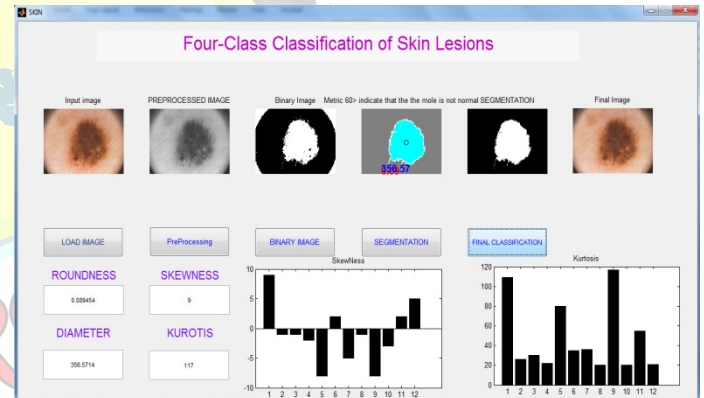


Figure 5.7 Final Classified Images

KURTOSIS

Measure of the degree of peachiness of a distribution. In some cases a distribution may have its values concentrated near the mean so the distribution has large peak. In other cases the distribution may be relatively flat. It gives about the central peak is high & sharp or short & broad.

SKEWNESS

Skewness is a measure of the asymmetry of a histogram. A distribution is said to be symmetric if it looks the same to the left and right of the centre point. If longer tails occurs to right the distribution is said to be skewed to right, while if the tails occurs to



the left it is said to be skewed to the left. Skewness can be defined as the ratio of the third cumulateK3 and the third power of the square root of the second cumulate.

V CONCLUSION

Skin cancer diagnosis system identifies and recognizes skin cancer symptoms and diagnoses melanoma in early stages. A review of skin cancer detection system has been done with the emphasis of the automated Computer Aided Diagnosis (CAD) of the present day. With the proper image input using different Digital Image Processing steps, doctors can get very good help from such diagnostic systems. We are proposing to use ABCD rule as its diagnostic accuracy has been reported to be 72%. A combination of both ABCD rules and wavelet coefficients has been shown to improve the image feature classification accuracy by 60%. At the end, we propose algorithm with relevant processing mathematics for proper, efficient detection of skin cancer. We hope that the proposed algorithm will help doctors. This system will save doctor's time and also can be used for regular monitoring skin cancer development in patients.

REFERENCES

- [1] Z. She and P. S. Excell, "Skin pattern analysis for lesion classification using local isotropy," *Skin Res. Technol.*, vol. 17, no. 2, pp. 206-212, May 2011.
- [2] R. Garnavi, M. Aldeen, M. E. Celebi, G. Varigos, and S. Finch, "Border detection in dermoscopy images using hybrid thresholding on optimized color channels," *Comput. Med. Imaging Graph.*, vol. 35, no.2, pp. 105-115, Mar. 2011.
- [3] R. Garnavi, M. Aldeen, and J. Bailey, "Computer-aided diagnosis of melanoma using border- and wavelet-based texture analysis," *IEEE Trans. Inf. Technol. Biomed.*, vol. 16, no. 6, pp. 1239-1252, Nov. 2012.
- [4] K. A. Norton, H. Iyatomi, M. E. Celebi, S. Ishizaki, M. Sawada, R. Suzaki, et al., "Three-phase general border detection method for dermoscopy images using non-uniform illumination correction," *Skin Res. Technol.*, vol. 18, no. 3, pp. 290-300, Aug. 2012.
- [5] M. E. Celebi, Q. Wen, S. Hwang, H. Iyatomi, and G. Schaefer, "Lesion border detection in dermoscopy images using ensembles of

thresholding methods," *Skin Res. Technol.*, vol. 19, no. 1, pp. e252-258, Feb. 2013.

[6] B. Cheng, R. Joe Stanley, W. V. Stoecker, S. M. Stricklin, K. A. Hinton, T. K. Nguyen, et al., "Analysis of clinical and dermoscopic features for basal cell carcinoma neural network classification," *Skin Res. Technol.*, vol. 19, no. 1, pp. e217-222, Feb. 2013.

ABOUT THE AUTHORS :

Asst. Prof. M.MALATHI is an assistant professor in the department of computer application at D.K.M. college for women , Vellore. Her special research interests are in Cloud computing, Data Mining, and Networks.

Asst. Prof. P.MOHANALAKSHMI is an assistant professor in the department of computer science at D.K.M. college for women , Vellore. Her special research interests are in Data Mining, Neural Networks and Robotics.